

EFFECT OF ORAL ADMINISTRATION OF *Lactobacillus acidophilus* ON THE INTESTINAL MUCOSAL IMMUNE CELLS IN YOUNG BACTRIAN CAMELS (*Camelus bactrianus*)

Shanshan Qi¹ and Hongxing Zheng^{1,2}

¹Shaanxi University of Technology, Hanzhong, Shaanxi 723000, China

²Key Laboratory of New Animal Drug Project, Gansu Province; Key Laboratory of Veterinary Pharmaceutical Development, Ministry of Agriculture, Lanzhou Institute of Husbandry and Pharmaceutical Sciences of CAAS, Lanzhou, Gansu 730050, China

ABSTRACT

The intention of this study was to examine the effects of oral administration of *L. acidophilus* L3 on the number of intestinal mucosal immune cells of young bactrian camels. Young camels were fed daily with *L. acidophilus* L3 (a concentration of 2×10^9 CFU/kg feed) and their intestinal immune cells were assessed on day 28 by the histology, histochemistry and cell counting methods. The number of intraepithelial lymphocytes (IELs), goblet cells (GCs), plasma cells and mast cells were counted, recorded and compared with the control group. Statistical analysis showed that the number of those intestinal mucosal immune cells were all increased in the probiotic group, compared with the control group and the difference was statistically significant ($P < 0.05$). The distribution tendency of those cells in small intestine was that: the number of intraepithelial lymphocytes, goblet cells and mast cells was gradually reduced from duodenum to ileum in two groups, whereas the number of plasma cells was gradually increased from duodenum to ileum. The results indicated that *L. acidophilus* L3 has intense influence on the number of mucosal immune cells in small intestine of young camels, supplementation of the diet with *L. acidophilus* L3 is able to enhance the intestinal mucosal immunity of young camels.

Key words: Immune cells, intestinal, *Lactobacillus acidophilus*, young camels

The intestinal microflora play a crucial role in host defense as demonstrated by their ability to modulate both innate and acquired immunity at the local as well as systemic levels (Isolauri *et al*, 2001; Macfarlane and Cummings, 2002). Due to these immunological properties, specific strains of lactic acid bacteria (LAB), defined as probiotics, have raised considerable interest in recent years. When ingested as a feed supplement in sufficient numbers, probiotics are live microorganisms that beneficially affect the gastrointestinal balance, going far beyond the conventional nutritional effect (Penner *et al*, 2005). Many studies report positive effects of probiotic supplementation on the performance and health of animals. Despite the fact that several studies have shown disease prevention or immune enhancement resulting from oral administration of probiotics (Biloo *et al*, 2006; Cong *et al*, 2003; Galdeano and Perdigon, 2006), few studies are available on their specific effects on the gut defense mechanisms, the mechanisms

underlying the immune modulating properties of probiotics are not fully understood.

Alashan bactrian camels inhabit the desert area of China where these were praised as “boat in the desert” in China. A deterioration of the environment, the gastrointestinal diseases leads to higher occurrence of causing more mortality of young camel is increased. It has been established in laboratory rodents that lactic acid bacteria given orally can significantly affect both the systemic and mucosa-associated immune responses (Perdigon and Alvarez, 1992). Despite the fact that several studies have shown disease prevention or immune enhancement resulting from oral administration of probiotics, few studies are available on their specific effects on the gut defense mechanisms in camels. The present work was conducted to help characterise some of these actions. The specific objective was to determine the effects of *L. acidophilus* L3 on the number of intestinal mucosal immune cells (intraepithelial lymphocytes, goblet cells, plasma cells and mast cells) of young camels.

SEND REPRINT REQUEST TO SHANSHAN QI email: qishanshan101@126.com

Materials and Methods

Study animals

All experimental procedures were approved by the Welfare Authority of Mingqing County of Gansu Province.

A group of 16 healthy young bactrian camels (1-1.5 years) was randomly divided into two groups, one of which (probiotic group) was supplemented with *L. acidophilus* L3 which was procured from China General Microbiological Culture Collection Center (CGMCC), while the other group of 8 camels remained untreated (control group). *L. acidophilus* L3 was provided to the probiotic group as a feed supplement at a concentration of 2×10^9 CFU/kg feed. The probiotic group received the food supplemented with *L. acidophilus* L3 for 28 days, then the animals were anaesthetised with sodium pentobarbital and were then exsanguinated. The small intestine of the probiotic group and the control group were investigated. Tissues were taken for histology from duodenum, distal jejunum and terminal ileum and fixed in a solution of 4% paraformaldehyde in 0.1 M phosphate buffer (pH 7.4) for 18 hr at 4°C and processed routinely for wax histology, paraffin sections were stained by the following methods: Haematoxylin and Eosin, Periodic Acid-Schiff, Unna-Pappenheim methyl green-pyronin and toluidine blue, to show intraepithelial lymphocytes (IELs), goblet cells, plasma cells and mast cells.

Cell count

(1) IELs and goblet cells were counted using the same standard microscope. The total number of IELs and goblet cells per 100 epithelial cells were counted at 400X magnification on Haematoxylin and Eosin stained slides and Periodic Acid-Schiff stained slides and the mean number was recorded for each case. Results were expressed as IELs/100 villus epithelial cells and GCs/100 villus epithelium cells. (2) The number of plasma cells and mast cells per 5 fields at a magnification of 400X was counted under light microscopy. These results were assessed semi

quantitatively by two authors and the average count was used as the final score.

Statistical analysis

All the data were analysed using Independent t-Test and One Way ANOVA (SPSS for Windows version 11.5). The statistical analysis was based on the comparison between the groups (using Independent t-Test) and comparison within the groups (using One Way ANOVA). Differences were considered statistically significant where $P < 0.05$.

Results

The comparison of the number of IELs in the probiotic group and the control group

As shown in Table 1, the number of IELs in small intestine of young camel in the probiotic group was more than control group. The difference between two groups was statistically significant ($P < 0.05$). The number of IELs in duodenum, jejunum and ileum increased by 59.97%, 62.54% and 54.52% in the probiotic group compared with the control group. The present investigation indicated that the number of IELs was gradually reduced from duodenum to jejunum in two groups.

The comparison of the number of goblet cells in the probiotic group and the control group

As shown in Table 2, the number of epithelial goblet cells in small intestine of camel in the probiotic group was more than the control group. The difference between two groups was statistically significant ($P < 0.05$). The number of epithelial goblet cells in duodenum, jejunum and ileum increased by 38.11%, 45.17% and 53.80% in the probiotic group compared with the control group. From duodenum to jejunum, the number of epithelial goblet cells was gradually reduced in two groups and the difference was statistically significant ($P < 0.05$).

The comparison of the number of plasma cells in the probiotic group and the control group

As illustrated in Table 3 the number of plasma cells in small intestine of camel in the probiotic group

Table 1. Number of intraepithelial lymphocytes in small intestine of young camel in the control and probiotic groups ($\bar{x} \pm s$).

Groups	IELs/100 villous epithelium cells			
	Duodenum	Jejunum	Ileum	Small intestinal
Control group	20.01±1.99 ^{Aa}	16.23±1.73 ^{Ba}	13.06±1.25 ^{Ca}	16.37±2.31 ^a
Probiotic group	32.01±3.04 ^{Ab}	26.38±3.17 ^{Bb}	20.18±2.03 ^{Cb}	26.19±3.95 ^b

The data with different capital letter within the same row or column differ significantly ($P < 0.05$). The capital letter (A, B, C) represent different small intestine segment in the same group, lowercase (a, b) represent the same small intestine segment in different group, the same as below.

was more than the control group and the difference between two groups was statistically significant ($P < 0.05$). At the same time, the number of plasma cells in duodenum, jejunum and ileum increased by 63.49%, 52.11% and 48.52% in the probiotic group compared with the control group. The number of plasma cells was gradually increased from duodenum to jejunum in two groups and the number of plasma cells in duodenum and jejunum was significantly different ($P < 0.01$), whereas, there was no difference in the number of plasma cells in jejunum and ileum ($P > 0.05$). Histological observation found that plasma cells were mainly distributed in the lamina propria of small intestine, there were few plasma cells in the solitary lymphoid nodule and aggregated lymphoid nodules.

The comparison of the number of mast cells in the probiotic group and the control group

The number of mast cells in the infected and normal group is shown in Table 4, we found that the number of mast cells in the probiotic group was higher than the control group and the difference between two groups was statistically significant ($P < 0.05$). The number of mast cells in duodenum, jejunum and ileum increased by 34.40%, 38.81% and 50.08% in the probiotic group compared with the control group. The number of mast cells was gradually decreased from duodenum to jejunum in two groups and the difference was statistically significant ($P < 0.01$). Histological observation demonstrated that mast cells were mainly distributed

around the intestinal gland, blood vessels and lymphatic vessels.

Discussion

This is the first report of the effects of oral administration of *L. acidophilus* L3 on the number of intestinal mucosal immune cells of young camels, the results of this study showed that all the immune cells (intraepithelial lymphocytes, goblet cells, plasma cells and mast cells) in small intestine of camel were increased in the probiotic group.

The intestinal tract is the crossroad between the needs of nutrient absorption and host defense (Macdonald and Monteleone, 2005). It has been suggested that the gut has the most important role in the maintenance of homeostasis of the body (Macdonald and Monteleone, 2005). As a complicated immune system tissue, the intestinal tract plays a critical role in the first line of defense against ingested pathogens. The main site of the mucosal immune system in the intestine is referred to as gut-associated lymphoid tissue and immune associated cells, including IELs, goblet cells, plasma cells and mast cells, are involved in many processes to prevent pathogen invasion (Oswald, 2006). The collaboration of those immunocompetent cells and probiotic help the animals to compete against all kinds of infectious pathogens (Blum and Schiffrin, 2003).

The gastrointestinal tract plays the key role in uptake of fluids and nutrients and at the same time it

Table 2. Number of goblet cells in small intestinal of young camel in the control and probiotic groups ($\bar{x} \pm s$).

Groups	GCs/100 villous epithelium cells			
	Duodenum	Jejunum	Ileum	Small intestinal
Control group	18.13±2.07 ^{Aa}	15.12±1.91 ^{Ba}	13.16±1.55 ^{Ca}	15.47±2.20 ^a
Probiotic group	25.04±3.11 ^{Ab}	22.03±2.34 ^{Bb}	20.24±2.54 ^{Cb}	22.44±3.08 ^b

The data with different capital letter within the same row or column differ significantly ($P < 0.05$). The capital letter (A, B, C) represent different small intestine segment in the same group, lowercase (a, b) represent the same small intestine segment in different group, the same as below.

Table 3. Number of plasma cells in small intestinal of young camel in the control and probiotic groups ($\bar{x} \pm s$).

Groups	Plasma cells / HPF			
	Duodenum	Jejunum	Ileum	Small intestinal
Control group	11.23±1.28 ^{Ba}	21.13±2.18 ^{Aa}	22.34±2.76 ^{Aa}	18.23±1.39 ^a
Probiotic group	18.36±2.04 ^{Bb}	32.14±3.87 ^{Ab}	33.18±3.45 ^{Ab}	27.89±3.01 ^b

Table 4. Number of mast cells in small intestinal of young camel in the control and probiotic groups ($\bar{x} \pm s$).

Groups	Mast cells / HPF			
	Duodenum	Jejunum	Ileum	Small intestinal
Control group	29.13±3.04 ^{Aa}	23.06±2.87 ^{Ba}	17.89±1.96 ^{Ca}	23.36±2.25 ^a
Probiotic group	39.15±4.12 ^{Ab}	32.01±3.98 ^{Bb}	26.85±2.94 ^{Cb}	32.67±3.23 ^b

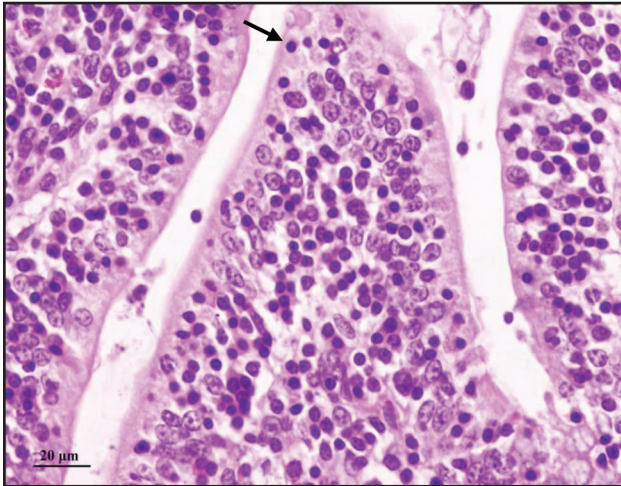


Fig 1. Light photomicrograph of the IELs in small intestine of young camel in the control group (H&E, bar=20µm). The arrow points to the IEL.

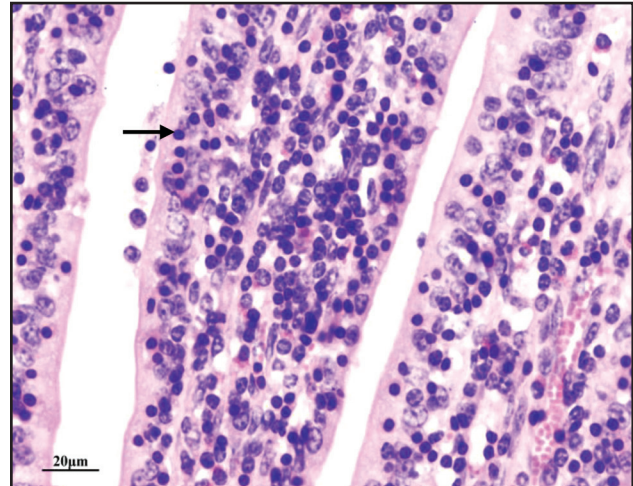


Fig 2. Light photomicrograph of the IELs in small intestine of young camel in the probiotic group (H&E, bar=20µm). The arrow points to the IEL.

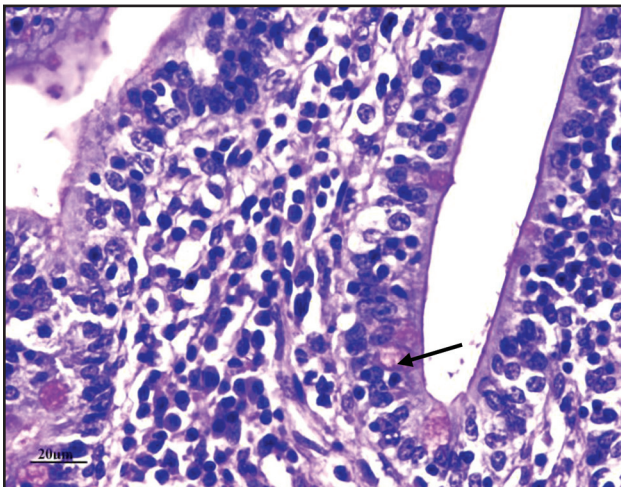


Fig 3. Light photomicrograph of the goblet cells in small intestinal epithelium of young camel in the control group (Periodic Acid-Schiff stain, bar=20µm). The arrow points to the goblet cell.

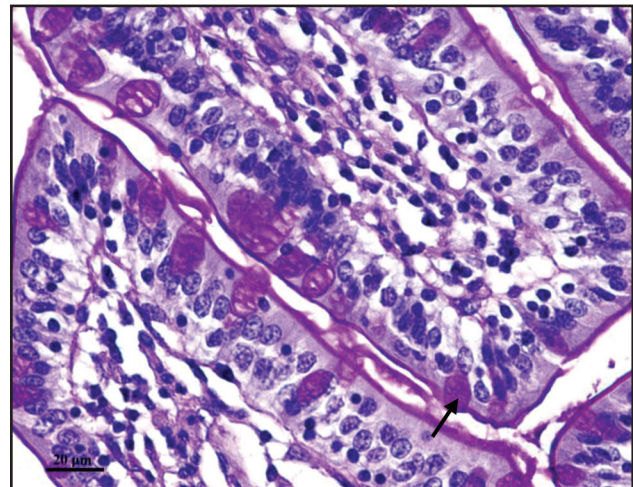


Fig 4. Light photomicrograph of the goblet cells in small intestinal epithelium of young camel in the probiotic group (Periodic Acid-Schiff stain, bar=20µm). The arrow points to the goblet cell.

forms the main protective barrier between the sterile environment of the body and the outside world (Artis, 2008). The intestinal intraepithelial lymphocytes (IELs) form the first line of the host immune defence system and play an essential role against infections caused by certain microorganisms or parasite (Guk *et al*, 2003; Inagaki-Ohara *et al*, 2006). This study found that the number of IELs in small intestine of camel in the probiotic group was more than normal group, at the same time, numerous investigators have demonstrated that raised IELs are often seen after feeding a probiotic. Dalloul *et al* (2003) examined the effects of feeding a Lactobacillus-based probiotic on the intestinal IEL subpopulations and any subsequent enhancement of intestinal immunity against coccidiosis, they found

that the number of IELs in the probiotic group was more than the control group, they also found that IELs sustain the epithelial barrier function against coccidiosis infection, during coccidiosis infection, IEL increased production of gamma interferon (IFN-gamma) and tumor necrosis factor alpha (TNF-alpha) and decreased transforming growth factor beta (TGF-beta) production. These results suggest that IEL play important multifunctional roles in protection of the epithelium against infections. The increased number of IELs in small intestine of young camels in this research indicate that *L. acidophilus* L3 has the function of immune stimulation, oral administration of *L. acidophilus* L3 can enhance the intestinal mucosal immunity.

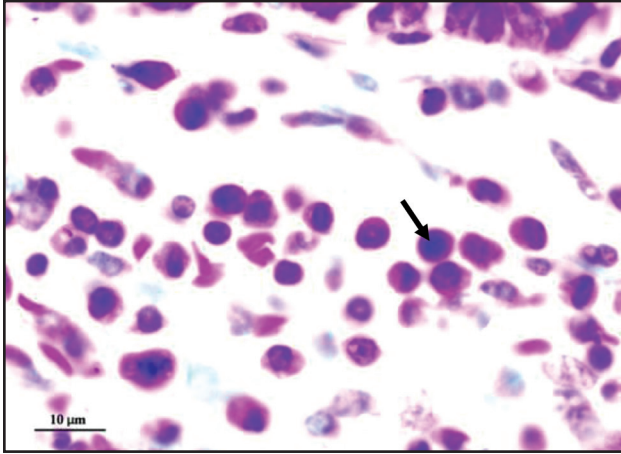


Fig 5. Light photomicrograph of the plasma cells in small intestine of young camel in the control group (Unna-Pappenheim methyl green-pyronin stain, bar=10µm). The arrow points to the plasma cell.

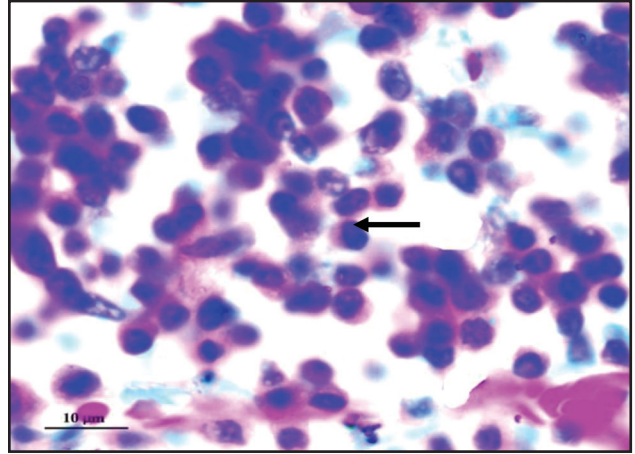


Fig 6. Light photomicrograph of the plasma cells in small intestine of young camel in the probiotic group (Unna-Pappenheim methyl green-pyronin stain, bar=10µm). The arrow points to the plasma cell.

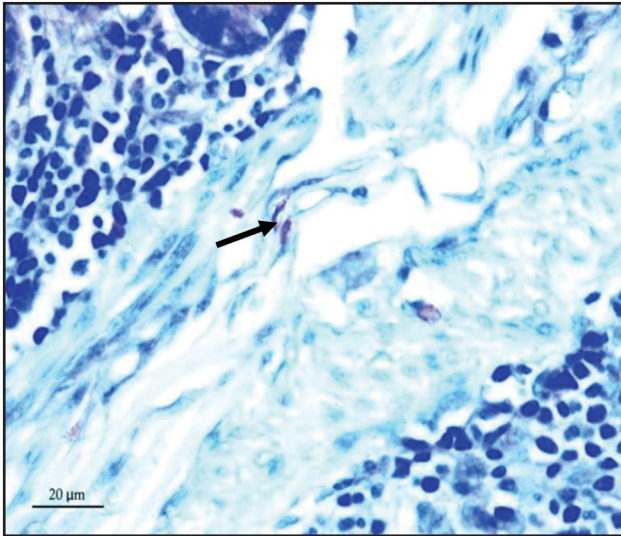


Fig 7. Light photomicrograph of the mast cells in small intestine of young camel in the control group (toluidine blue stain, bar=20µm). The arrow points to the mast cell.

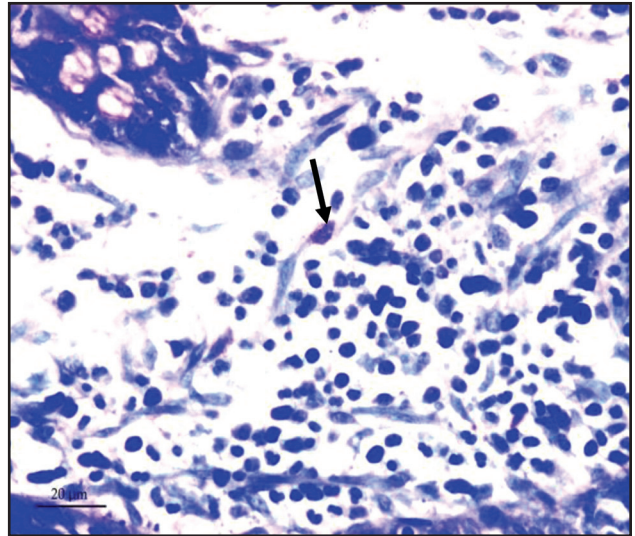


Fig 8. Light photomicrograph of the mast cells in small intestine of young camel in the probiotic group (toluidine blue stain, bar=20µm). The arrow points to the mast cell.

The study find that the number of epithelial goblet cells in small intestine of camel in the probiotic group was more than the control group. We know that goblet cell can secrete mucins, mucins are the major protein components of the protective mucus barrier that cover epithelial surfaces in the gastrointestinal tract. This barrier is considered a first line of defense against colonisation by gut pathogens (Harrison *et al*, 1999). Mahdavi *et al* (2005) found using different levels of probiotic caused highly significant increase ($P < 0.01$) in goblet cell numbers, they provide the probiotic feed containing *Bacillus subtilis* (CH201) and *Bacillus licheniformis* (CH200) to hens for 12 weeks, the number of intestinal goblet

cells markedly increased in the probiotic group. Another research also found that the dietary probiotic significantly increase the number of goblet cells and mucins throughout the small intestine compared with the other groups in chickens (Smirnov *et al*, 2005). Goblet cell mucins play a key role in mucosal defence, it seem as the selective barrier for the intestinal pathogens, thus the increase in the number of goblet cells seem to be an unspecific defensive mechanism. The hyperplasia of epithelial goblet cells in small intestine of camels show that *L. acidophilus* L3 has the function of immune stimulation, oral administration of *L. acidophilus* L3 can reinforcement of the intestinal mucosal barrier against infection.

Our study found that the number of plasma cells in each part of the small intestine in the probiotic group was more than that of the control group and the difference between two groups was statistically significant. The main function of plasma cells is to produce immunoglobulin A (IgA), most of the IgA in the gut is generated by B cells in the PP germinal centers (McGhee, 2005; Mestecky and Elson, 2008). On epithelial surfaces, the main specific immune defense of the host is the protection afforded by secretory IgA antibodies. In a study of Jain *et al* (2008), the protective effect of probiotic dahi supplemented with *Lactobacillus acidophilus* and *L. casei* against *Salmonella enteritidis* infection in mice is investigated. Seven days pre-feeding with probiotic dahi significantly increased *anti-S. enteritidis* secretory IgA antibodies and lymphocyte proliferation in *S. enteritidis* infected mice. The mucosal immune system forms the largest part of the entire immune system, containing about three quarters of all lymphocytes and producing grams of secretory IgA daily to protect the mucosal surface from pathogens (Macpherson, 2006). A great deal of IgA secreted by plasma cells can prevent the pathogens inhabiting.

The probiotic group showed apparently higher number of mast cells in each part of the small intestine than that of the control group. The increase of mast cell in the intestinal mucosa is known to play an important role in host defense against infections (Caldwell *et al*, 2004; Zareie *et al*, 2006). Some studies indicate that intestinal mucosal mast cells play an important role in the local mucosal immune response (Caldwell *et al*, 2004; Morris *et al*, 2004). Mast cells are important immunocompetent cells in the intestinal mucosal immune response that exert multifunctional roles by releasing prestored and de novo synthesised mediators such as histamine, proteases, serotonin and others (Metcalf *et al*, 1997).

Our present research supported that the specific effects on the gut defense mechanisms was that *L. acidophilus* L3 has intense influence on the number of mucosal immune cells, the increased intestinal mucosal immune cells can enhance the defense system of the body, so the diarrhea, mortality and morbidity will be decreased.

Conclusions

The present study suggests that *L. acidophilus* L3 has intense influence on the number of mucosal immune cells (IELs, goblet cells, plasma cells and mast cells) in small intestine of young camels, the hyperplasia of those cells can strengthen the anti-

infections ability of camels. The main action of *L. acidophilus* L3 can be summarised as a reinforcement of the intestinal mucosal barrier and increase the number of intestinal mucosal immune cells.

Acknowledgments

This research was supported by the open fund of the Key Laboratory of the New Animal Drug Project of Gansu Province and the Key Laboratory of Veterinary Pharmaceutical Development of the Ministry of Agriculture (1610322011011), Natural Science Foundation of the Education Department of Shaanxi Province (2013JK0721), Foundation of Shaanxi University of Technology (SLGQD13-19).

Reference

- Artis D (2008). Epithelial-cell recognition of commensal bacteria and maintenance of immune homeostasis in the gut. *Nature Reviews Immunology* 8:411-420.
- Billoo AG, Memon MA, Khaskheli SA, Murtaza G, Iqbal K, Saeed Shekhani M and Siddiqi AQ (2006). Role of a probiotic (*Saccharomyces boulardii*) in management and prevention of diarrhoea. *World Journal of Gastroenterology* 12:4557-4560.
- Blum S and Schiffrin EJ (2003). Intestinal microflora and homeostasis of the mucosal immune response: implications for probiotic bacteria? *Current Issues in Intestinal Microbiology* 4:53-60.
- Caldwell DJ, Danforth HD, Morris BC, Ameiss KA and McElroy AP (2004). Participation of the intestinal epithelium and mast cells in local mucosal immune responses in commercial poultry. *Poultry Science* 83:591-599.
- Cong Y, Konrad A, Iqbal N and Elson CO (2003). Probiotics and immune regulation of inflammatory bowel diseases. *Current Drug Targets Inflammation and Allergy* 2:145-154.
- Dalloul R, Lillehoj H, Shellem T and Doerr J (2003). Enhanced mucosal immunity against *Eimeria acervulina* in broilers fed a *Lactobacillus*-based probiotic. *Poultry Science* 82:62-66.
- Galdeano CM and Perdigon G (2006). The probiotic bacterium *Lactobacillus casei* induces activation of the gut mucosal immune system through innate immunity. *Clinical and Vaccine Immunology* 13:219-226.
- Guk SM, Yong TS and Chai JY (2003). Role of murine intestinal intraepithelial lymphocytes and lamina propria lymphocytes against primary and challenge infections with *Cryptosporidium parvum*. *Journal of Parasitology* 89:270-275.
- Harrison GB, Pulford HD, Gatehouse TK, Shaw RJ, Pfeffer A and Shoemaker CB (1999). Studies on the role of mucous and mucosal hypersensitivity reactions during rejection of *Trichostrongylus colubriformis* from the intestine of immune sheep using an experimental challenge model. *International Journal for Parasitology* 29:459-468.

- Inagaki-Ohara K, Dewi FN, Hisaeda H, Smith AL, Jimi F, Miyahira M, Abdel-Aleem AS, Horii Y and Nawa Y (2006). Intestinal intraepithelial lymphocytes sustain the epithelial barrier function against *Eimeria vermiciformis* infection. *Infection and Immunity* 74:5292-5301.
- Isolauri E, Sutas Y, Kankaanpaa P, Arvilommi H and Salminen S (2001). Probiotics: effects on immunity. *American Journal of Clinical Nutrition* 73:444S-450S.
- Jain S, Yadav H, Sinha PR, Naito Y and Marotta F (2008). Dahi containing probiotic *Lactobacillus acidophilus* and *Lactobacillus casei* has a protective effect against *Salmonella enteritidis* infection in mice. *International Journal of Immunopathology and Pharmacology* 21:1021-1029.
- Macdonald TT and Monteleone G (2005). Immunity, inflammation and allergy in the gut. *Science* 307:1920-1925.
- Macfarlane GT and Cummings JH (2002). Probiotics, infection and immunity. *Current Opinion in Infectious Diseases* 15:501-506.
- Macpherson AJ (2006). IgA adaptation to the presence of commensal bacteria in the intestine. *Current Topics in Microbiology and Immunology* 308:117-136.
- Mahdavi AH, Rahmani HR and Pourreza J (2005). Effect of probiotic supplements on egg quality and laying hen's performance. *International Journal of Poultry Science* 4:488-492.
- McGhee JR (2005). Peyer's patch germinal centers: the elusive switch site for IgA. *Journal of Immunology* 175:1361-1362.
- Mestecky J and Elson CO (2008). Peyer's patches as the inductive site for IgA responses. *Journal of Immunology* 180:1293-1294.
- Metcalfe DD, Baram D and Mekori YA (1997). Mast cells. *Physiol Rev* 77:1033-1079.
- Morris BC, Danforth HD, Caldwell DJ, Pierson FW and McElroy AP (2004). Intestinal mucosal mast cell immune response and pathogenesis of two *Eimeria acervulina* isolates in broiler chickens. *Poultry Science* 83:1667-1674.
- Oswald IP (2006). Role of intestinal epithelial cells in the innate immune defence of the pig intestine. *Veterinary Research* 37:359-368.
- Penner R, Fedorak RN and Madsen KL (2005). Probiotics and nutraceuticals: non-medicinal treatments of gastrointestinal diseases. *Current Opinion in Pharmacology* 5:596-603.
- Perdigon P and Alvarez S (1992). Probiotics and the immune state. *Probiotics: The Scientific Basis*. R. Fuller, ed. Chapman and Hill, London. pp 145-180.
- Smirnov A, Perez R, Amit-Romach E, Sklan D and Uni Z (2005). Mucin dynamics and microbial populations in chicken small intestine are changed by dietary probiotic and antibiotic growth promoter supplementation. *Journal of Nutrition* 135:187-192.
- Zareie M, Johnson-Henry K, Jury J, Yang PC, Ngan BY, McKay DM, Soderholm JD, Perdue MH and Sherman PM (2006). Probiotics prevent bacterial translocation and improve intestinal barrier function in rats following chronic psychological stress. *Gut* 55:1553-1560.